

c0440

s0010
p0010**1. What is a genioplasty?**

Genioplasty is an operation on the chin that uses either an osteotomy or an implant to change the position of the chin.

s0020
p0015**2. How do you determine the relationship of the nose to the chin?**

The ratio of nasal projection to nasal length should be 2:3. Assuming nasal projection and nasal length are correct, the aesthetic balance between the nose and chin can be clinically assessed. If the chin appears too far anterior or posterior to the nose, the occlusion should be evaluated. Orthognathic surgery can be done to correct skeletal malocclusions. If the patient does not desire orthognathic surgery or if the occlusal discrepancies are minimal, a genioplasty can be performed to minimize the chin deformity.

s0025
p0020**3. What factors determine sagittal projection of the chin?**

The lower lip and the nose play an important role in chin aesthetics. Several tools can be used to assess chin projection. If nasal length is ideal, a line can be dropped from the midsom of the nose inferior and tangential to the upper lip. According to Byrd, the chin should be approximately 3 mm posterior to this line. Another method is to drop a line inferior and perpendicular to Frankfurt horizontal that is tangential to the lower lip. The chin should be just posterior to this line in females and at, or slightly anterior to, this line in males. A final analysis is Riedel's line. This line connects the most prominent points of the upper and lower lips. The most prominent point of the chin should be the third point on this line. These references are general guidelines. Each patient's particular facial shape, skeletal form, and soft tissue characteristics should be taken into account. For instance, in a patient with a mandibular retrognathia whose occlusion has been compensated, it would be inadvisable to move the chin as far forward to the ideal position because of adverse changes in the labiomental crease. An undercorrection in this case may give an improvement that is more aesthetically pleasing than moving the chin into the "ideal" position.

s0030
p0025**4. What is the relationship of the soft tissue to hard tissue when the chin is moved?**

The response of the soft tissue to a genioplasty is better than is the soft tissue response to an implant. Because the mentalis attaches the skin to the bone of the anterior chin, the skin will move in a 1:1 relationship with the bone in a genioplasty. When an implant is used, the soft tissue to implant response is 0.8:1. This is a useful guide when doing prediction tracings of the anticipated chin position and its relationship to the nose.

s0035
p0030**5. What factors determine the vertical position of the chin?**

The vertical height of the face can be divided into thirds. The trichion to the glabella is the upper third, the glabella to subnasale is the middle third, and subnasale to menton is the lower third. The vertical height of the chin should be set so that the lower third of the face is approximately equal to the upper and middle thirds. Another factor that affects the aesthetics of the vertical height of the chin is the depth of the labiomental crease. The crease should not exhibit effacement nor should it be deep. Moving the chin forward or superior will deepen the crease. Moving the chin inferiorly or posteriorly will efface the crease. These anticipated changes should be taken into account when developing a treatment plan to change the vertical height of the chin. In an advancement genioplasty, the surgeon must be careful to ensure that the osteotomy is parallel to Frankfurt horizontal. If the osteotomy is angled superiorly from anterior to posterior, the chin will become elongated as it is advanced (see Pharaoh deformity, Question 12).

s0040
p0035**6. What factors determine the transverse position of the chin?**

The clinical evaluation often reveals whether the midline discrepancy is due to osseous tissue, soft tissue, or a combination of both. When examining the facial midline, it is useful to mark several points (glabella, nose, dental midlines, vermilion, chin) to see if all are congruent. Occasionally, these points are not aligned, and the surgeon needs to point this out to the patient preoperatively to explain the limitations of surgery. Ideally, the center of the chin is congruent with the mandibular skeletal and dental midlines. If the chin is not centered, a simple centering genioplasty is indicated. If the chin as well as the mandibular midline is not centered, a mandibular osteotomy is necessary to correct the asymmetry. Occasionally, the mandible and the chin both require independent movements to achieve the best result. When the chin is moved, a 1:1 ratio of bone to soft tissue movement is anticipated when planning the final position.

- s0045
p0040
- 7. What imaging is necessary prior to osseous genioplasty?**
A panoramic radiograph (Panorex) should be obtained prior to performing an osseous genioplasty to rule out the presence of periapical or other bony pathology. This image helps differentiate any osseous component of chin asymmetry from that related to soft tissue. Important diagnostic information regarding the deformity also can be assessed, such as asymmetry, vertical height, proximity of tooth roots to proposed osteotomy, and location of the mental foramen. A lateral cephalometric radiograph is helpful for predicting the degree of movement required to obtain the desired result.
- s0050
p0045
- 8. How does the concept of skeletal expansion apply to the chin?**
Moving the chin anteriorly or superiorly deepens the labiomental crease. In contrast, inferior or posterior movements soften the labiomental crease. In the patient with a normal crease, an anterior movement will create a deep crease. This effect can be negated by moving the chin inferiorly if the patient's facial shape can tolerate the change. Otherwise, it is advisable to reduce the degree of anterior advancement. If a patient with an effaced crease requires an inferior movement, the surgeon should also move the chin forward, if possible, to normalize the crease. Frequently, compromises are required, and it is up to the surgeon to plan the ideal movements based on each patient's preoperative facial dimensions.
- s0055
p0050
- 9. When is an osseous genioplasty preferable to a chin implant?**
A chin implant is only capable of increasing chin projection. A chin implant cannot change the vertical dimension of the chin nor can it correct transverse asymmetry. An osseous genioplasty is the only method for manipulating the chin in all three dimensions. Additionally, an osseous genioplasty will advance the genial tubercles and thus the suprahyoid musculature. This advancement produces an improvement in the neck–chin contour that is not as pronounced as the neck tightening seen with implants.
- s0060
p0055
- 10. What are the advantages to alloplastic chin augmentation?**
An implant can add volume to the lateral mandible, which can increase lower facial width; often this is useful in patients with small pointed chins. There is less risk to the mental nerve with the submental incision and dissection used to place a chin implant. If the patient does not like the implant, it can be removed. However, if the implant is removed, a slight soft tissue droop due to compromise of the attachment of the mentalis to the bone may be noted.
- s0065
p0060
- 11. Where should the incision be placed for a chin implant?**
A submental incision is the best choice for inserting a chin implant. This reduces the chance of the implant migrating in a superior direction. Because the mentalis is not violated, the risk of witch's chin deformity is reduced. This incision is easy to make under local anesthesia with or without sedation, making insertion of a chin implant an easy procedure to perform in the office.
- s0070
p0065
- 12. What potential adverse aesthetic effects are associated with advancement genioplasty? What is a Pharaoh deformity?**
When an osseous genioplasty is advanced more than 5 to 6 mm, a notch can occur at the junction of the segments. Typically, this resolves as the bone resorbs, but if it persists beyond 6 months, a bone graft or implant can be placed to minimize the notch and smooth the mandibular contour in this region. An overadvanced chin also can cause excessive deepening of the labiomental crease, creating a prematurely aged appearance. The labiomental crease should never be more than 4 mm in women and no more than 6 mm in men. Additionally, excessive vertical elongation can occur as the chin is advanced. This can elongate the lower facial third and create a very unaesthetic appearance, especially in a patient who exhibits a long lower face preoperatively. This elongation leads to a "Pharaoh deformity," which is an elongated narrow chin (Fig. 88-1).
- s0075
p0070
- 13. What potential adverse esthetic effects are associated with setback genioplasty?**
Only an osseous genioplasty can be done to reduce the projection of the chin. You must be careful not to posteriorly position the chin excessively because of the potential to create soft tissue redundancy in the submental region. Also, as the symphysis of the chin is posteriorly positioned, a boxy appearance can be created as the facial shape becomes more square and loses the ideal oval shape. For these reasons, posterior movements of the chin should not be more than 3 to 4 mm in most cases. Patients should be warned preoperatively that they will have a palpable step where the edge of the posteriorly placed chin is wider than the mandible. Typically this irregularity resolves over several months as the bone resorbs, but if this step-off is noted to be excessive at the time of genioplasty, it can be reduced with the burr at the time of surgery.
- s0080
p0075
- 14. How much subperiosteal dissection is recommended to perform an osseous genioplasty?**
As little subperiosteal reflection as possible is done to visualize the mental nerves and apply fixation. Limiting the dissection will minimize chin ptosis (witch's chin) and maintain a 1:1 ratio of osseous to soft tissue during the movements. Retractors are used to visualize the nerve and retract it away from the saw during the osteotomy.



Figure 88-1. The Pharaoh deformity.

f0010

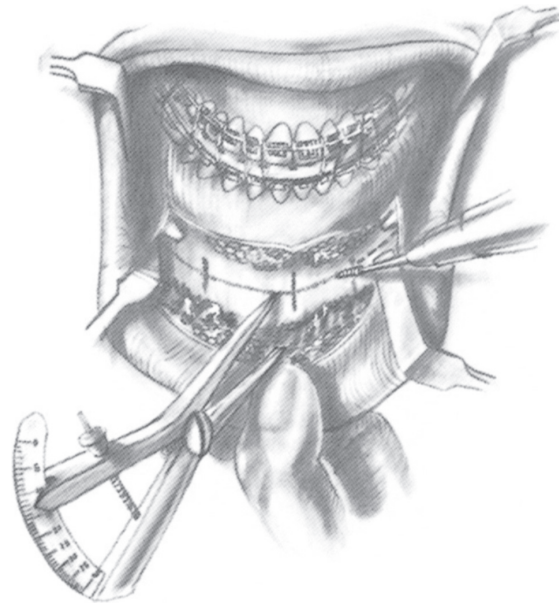


Figure 88-2. Calipers are used to make measurements and verify chin position. Vertical drill lines are used to maintain orientation after the chin has been osteotomized. (From Bell WH [ed]: *Modern Practice in Orthognathic and Reconstructive Surgery*, Vol 3. Philadelphia, WB Saunders, 1992, p 2448.)

f0015

15. Where are the osteotomy cuts made?

The cuts should be made 5 mm below the mental foramen and should extend posteriorly to the molar region. This posterior extension keeps the osteotomy transition under the thicker soft tissues of the mandibular angle. The posterior extension also minimizes the hourglass deformity, which can occur when the cuts are made too far anteriorly (Fig. 88-2).

16. What are the various types of genioplasties?

- *Sliding Genioplasty*: This osteotomy is performed as a single cut through the chin at least 5 mm inferior to the apices of the mandibular teeth. It allows the chin segment to be moved anteriorly or posteriorly while maintaining contact between the two bone segments. Prefabricated chin plates can be used to easily secure the segments when in the desired position (Fig. 88-3).
- *Jumping Genioplasty*: The jumping genioplasty is performed by making an osteotomy cut through the inferior mandible and then bringing the segment forward and superior so that the posterior edge of the chin segment rests against the anterior portion of the inferior mandible.
- *Reduction Genioplasty*: This is done when the vertical height of the chin is excessive and the maxillary vertical position is normal. Two parallel cuts are made, with the distance between the cuts corresponding to the degree of vertical reduction desired. It is useful to make the inferior osteotomy cut first so that the second cut is still on stable bone as opposed to making the second cut on a mobile chin segment (Fig. 88-4).
- *Double Step Genioplasty*: This osteotomy is indicated in cases of severe deficiency. A double cut is made (inferior portion first). The upper osteotomized portion is advanced and secured to the intact mandible. The inferior segment is moved anteriorly and secured to the middle segment while maintaining bony overlap at each area of advancement (Fig. 88-5).
- *Vertical Elongating Genioplasty*: The osteotomy is performed, and a bone graft or piece of block hydroxyapatite is placed interpositionally to maintain the gap between the segments as the lower portion of the chin is inferiorly displaced (Fig. 88-6).
- *Widening Genioplasty*: A narrow chin can be widened by doing a horizontal osteotomy cut and then dividing the inferior portion of the chin at the midline with a vertical osteotomy. The inferior pieces can be widened using a bone graft or block hydroxyapatite as a midline spacer for stability.

17. What are the potential complications of an osseous genioplasty?

Potential complications of an osseous genioplasty include asymmetry, wound dehiscence, overadvancement or underadvancement, chin ptosis, and lip paresthesia. Despite the multitude of potential complications, their frequency is rare (<5%).

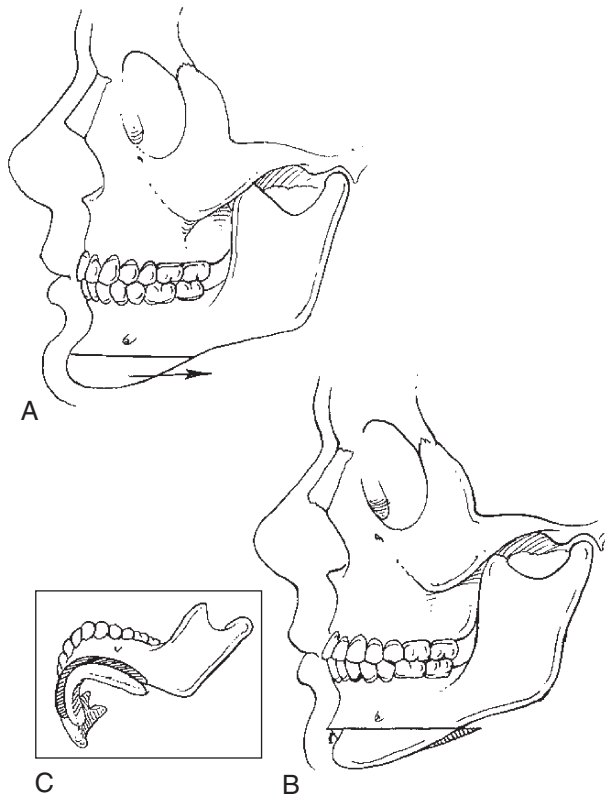


Figure 88-3. Horizontal osteotomy with setback. **A**, Sliding genioplasty osteotomy requires special attention laterally at the inferior border (**B, C**) to ensure a smooth transition between the mobilized segment and mandible. (From Fonseca RJ [ed]: *Oral and Maxillofacial Surgery*, Vol 2, Orthognathic Surgery, Betts NJ, Turvey TA [eds]. Philadelphia, WB Saunders, 2000.)

f0020

AU2

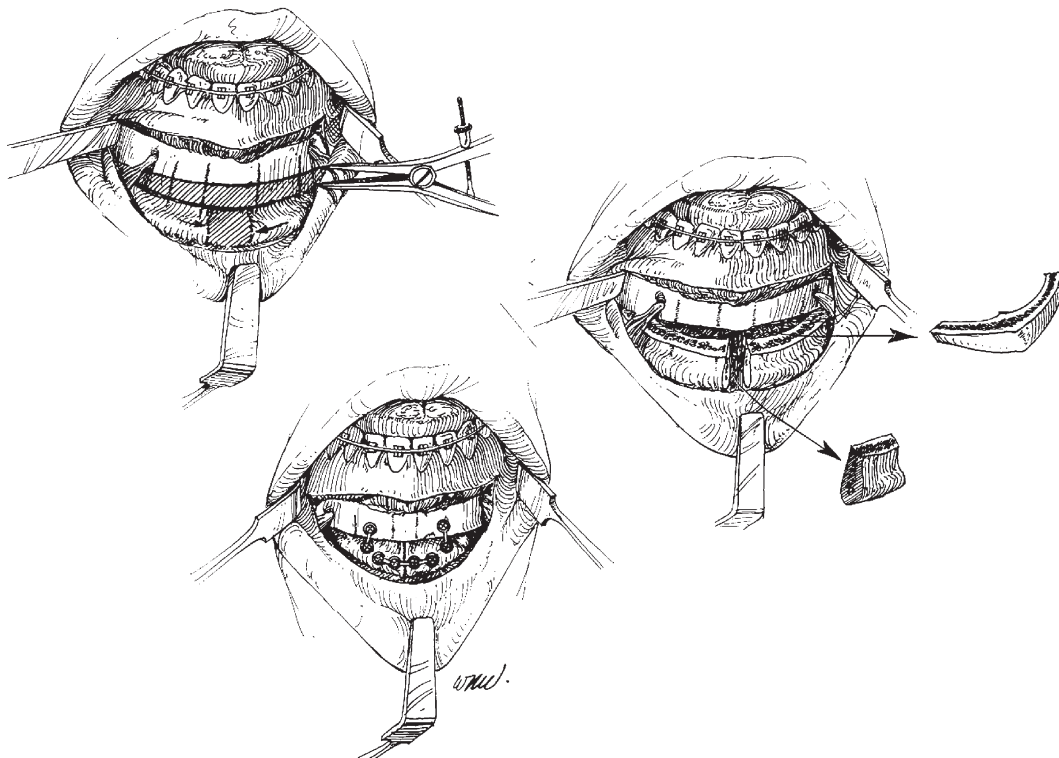
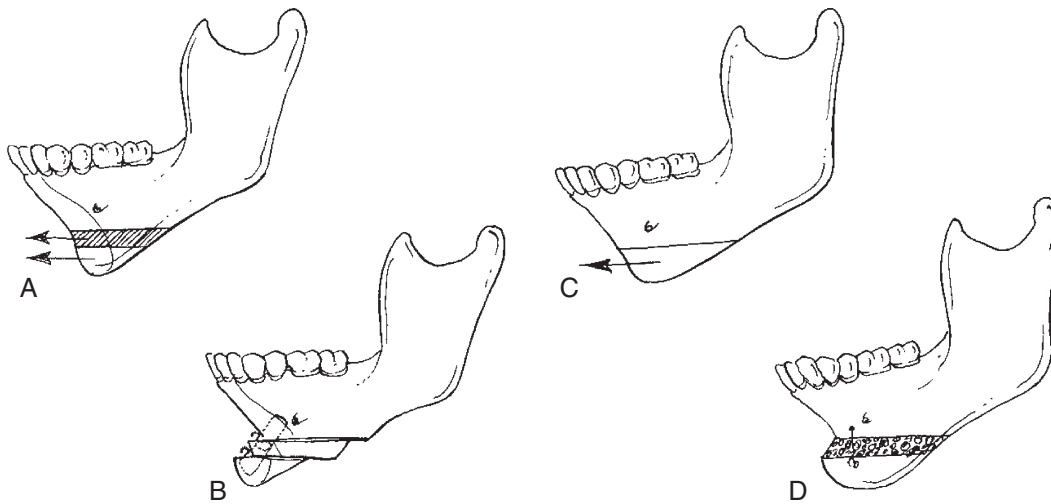
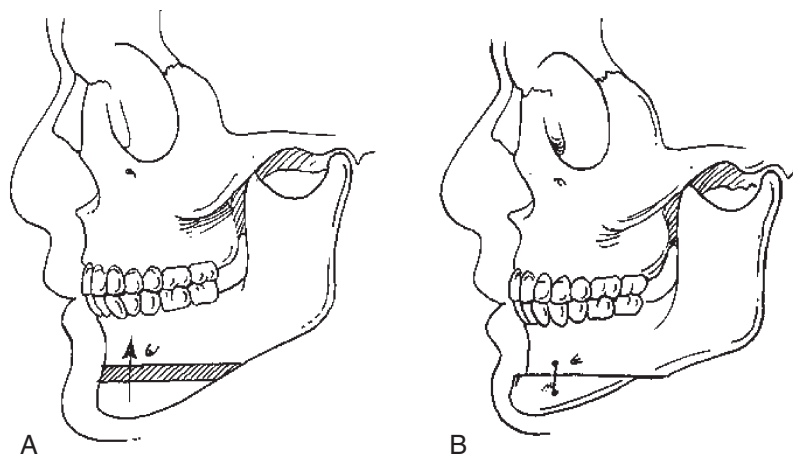


Figure 88-4. Reduction genioplasty. Narrowing of the inferior chin can be achieved by removing a central block of bone and moving the lateral segments to the midline. Rigid fixation is used to maintain the position of the segments. (From Bell WH [ed]: *Modern Practice in Orthognathic and Reconstructive Surgery*, Vol 3, Philadelphia, WB Saunders, 1992, p 2470.)



r0030 **Figure 88-5.** Double sliding genioplasty. **A**, This osteotomy can be used in cases of severe deficiency. **B–D**, Often, it is necessary to provide grafts over the step defects to ensure a predictable contour. (From Fonseca RJ [ed]: *Oral and Maxillofacial Surgery*, Vol 2, Orthognathic Surgery, Betts NJ, Turvey TA [eds]. Philadelphia, WB Saunders, 2000.)

AU3



r0035 **Figure 88-6.** Wedge vertical reduction osteotomy. This osteotomy allows for **(A)** anteroposterior repositioning in addition to **(B)** vertical shortening. (From Fonseca RJ [ed], *Oral and Maxillofacial Surgery*, Vol 2, Orthognathic Surgery, Betts NJ, Turvey TA [eds]. Philadelphia, WB Saunders, 2000.)

AU4

s0100 **18. What are the potential complications of a chin implant?**

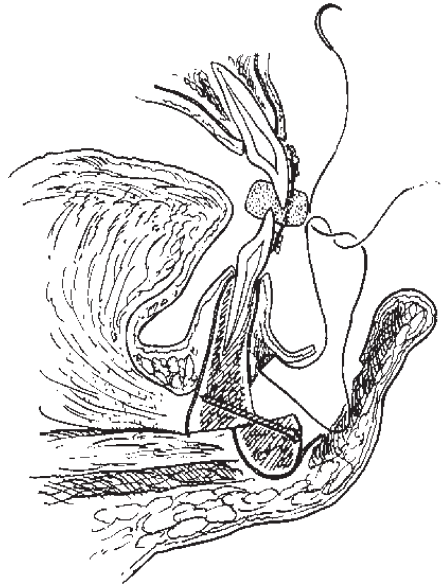
p0125

The potential complications of chin implantation include selection of the wrong size or shape implant, infection, extrusion, malposition, capsular contracture, and chin ptosis. For chin implantation, the risk of a complication is low but is slightly higher than that of osseous genioplasty.

s0105 **19. What is a witch's chin deformity?**

p0130

The “witch’s chin deformity” results from a transection of the mentalis muscle that is not properly reapproximated. It is characterized by a clockwise rotation of the soft tissue in the chin causing it to droop over the osseous menton. At closure of the intraoral incision, the mentalis should be closed with several interrupted resorbable sutures to prevent this. Care must be taken to prevent dimpling of the skin that results from excessively deep bites (Fig. 88-7).



10040 **Figure 88-7.** Mentalis is reapproximated with 2-0 monocryl as the chin is closed. This maintains proper position of the lower lip and reduces the chance of developing a witch's chin. (From Bell WH [ed]: *Modern Practice in Orthognathic and Reconstructive Surgery*, Vol 3. Philadelphia, WB Saunders, 1992, p 2451.)

BIBLIOGRAPHY

1. Bell WH (ed): *Modern Practice in Orthognathic and Reconstructive Surgery*. Philadelphia, WB Saunders, 1992, pp 2431–2488.
2. Byrd HS, Burt J: Dimensional approach to rhinoplasty: perfecting the aesthetic balance between the nose and chin. In Gunter JP, Rohrich RJ, Adams WP (eds): *Dallas Rhinoplasty: Nasal Surgery by the Masters*. St. Louis, Quality Medical Publishing, 2002.
3. Fonseca RJ (ed): *Oral and Maxillofacial Surgery*. Philadelphia, WB Saunders, 2000.
4. Riedel RA: An analysis of dentofacial relationships. *Am J Orthod* 43:103, 1957.
5. Guyuron B: Genioplasty. In Goldwyn RM, Cohen M (eds): *The Unfavorable Result in Plastic Surgery: Avoidance and Treatment*, 3rd ed. Philadelphia, Lippincott Williams & Wilkins, 2001, pp1036–1042.
6. Rosen HM: Aesthetic refinements in genioplasty: The role of the labiomental fold. *Plast Reconstr Surg* 88:760–767, 1991.
7. Rosen HM: Aesthetic guidelines in genioplasty: The role of facial disproportion. *Plast Reconstr Surg* 95:463–469, 1995.
8. Rosen HM: *Aesthetic Perspectives in Jaw Surgery*. New York, Springer Verlag, 1997, pp 247–272.

AU1

Author Query Form

Book: Plastic Surgery Secrets
Chapter No.: 00088

Query	Details Required	Author's Response
[AU1]	Pls. supply page range	
[AU2]	Pls. supply page range	
[AU3]	Pls. supply page range	
[AU4]	Pls. supply page range	