

Orthognathic Surgery for Cleft Lip/Palate

*Stephen Baker • Nathan Menon
Jeffrey Weinzweig*



Orthognathic surgery for correcting dentofacial deformities is often a complex undertaking in patients with clefts. Although the goal of orthognathic surgery in all patients is ideal occlusion, in patients with clefts this often requires performing multiple-segment osteotomies, overcoming the scar-tissue impediment to maxillary advancement, and taking into account poor bone stock, factors which must be carefully considered and accurately evaluated during the preoperative planning stages. A comprehensive strategy that addresses each of these variables is of paramount importance for achieving an excellent result.

As many as 25% to 30% of patients who have undergone surgical correction of cleft lip and palate develop midface retrusion severe enough to require orthognathic correction. Maxillary hypoplasia resulting in class III malocclusion is the typical deformity seen in this patient population. The cause of maxillary hypoplasia is twofold. Evidence shows that inelastic scar tissue from the original palatoplasty restricts facial growth and suggests an intrinsic midfacial growth deficiency unrelated to surgery (that is, it is an inherent component of the congenital anomaly)¹. Although mild class III malocclusions may be treated with orthodontics alone, orthognathic surgery is needed to ideally correct a class III dentofacial deformity.

PREOPERATIVE EVALUATION

The chance of a favorable surgical outcome is optimized if presurgical planning is performed in conjunction with a cleft/craniofacial team. Speech pathologists play an integral role in evaluating the velopharyngeal mechanism and the potential effects that maxillary advancement may

have on speech nasality and articulation. Preoperative videonasoscopy has been shown to yield information that can aid in predicting postoperative hypernasality.

The orthodontist's role in preoperative evaluation and management is critical. Before surgery, the potential surgical candidate requires a comprehensive workup that includes an analysis of occlusal characteristics and the age of the facial skeleton. The age of the facial skeleton is important because orthognathic surgery should be performed after facial growth is complete. If orthognathic surgery is attempted before the facial skeleton reaches maturity, the need for revision surgery is increased because of continued postoperative growth. Skeletal growth is usually complete between the ages of 14 and 16 years in females and between the ages of 16 and 18 years in males. The maturity of the facial skeleton and the cessation of growth can be assessed using serial cephalometric radiographs or by looking for epiphyseal closure in hand radiographs.

Cephalometric and dental radiographs should also be obtained before surgery to quantify the extent of hypoplasia/retrusion in three dimensions. A cephalometric analysis and comparison with normative values can help the surgeon plan the amount of skeletal movement needed to achieve both an optimal occlusion and an optimal aesthetic result. Complete dental records, including mounted dental casts, are needed to execute preoperative model surgery and fabricate surgical splints (see Chapter 27). The orthodontist's role in preoperative planning is critical to the success of the operation. The desired occlusion is achieved by moving the jaws to a class I dental relationship. This can be accomplished by moving the maxilla, the mandible, or both. The choices of appropriate osteotomies and directions of movement are determined by their anticipated effects on occlusion, speech nasality, and facial aesthetics.

Once a treatment plan has been developed from the physical examination and the cephalometric analysis, model surgery is undertaken on plaster casts of the mandible and maxilla. Model surgery starts by obtaining accurate casts of the patient's occlusion. If the surgeon does not have a dental laboratory, the orthodontist can help with obtaining casts. It is important to obtain accurate casts, because the success of the technical portion of orthognathic surgery correlates directly with the accuracy of the model surgery and splint fabrication.

A face bow is a device used to accurately relate the maxillary model to the cranium on an articulator. If a maxillary osteotomy is being performed, one set of models should be mounted on an articulator using the face bow. Two other sets of models are used for treatment planning. An Erickson model block is used to measure the position of the maxillary central incisors, cuspids, and the mesiobuccal cusp of the first molar. The face bow-mounted maxillary cast is placed on the model block. The maxillary model is measured to a tenth of a millimeter vertically, anteroposteriorly, and end-on. By having numerical records in three dimensions, the surgeon can reproduce the maxillary cast's exact location as well as determine new locations. Reference lines are circumferentially inscribed every 5 mm around the maxillary cast mounting. The distances the maxilla is to move anteroposteriorly, laterally, and vertically will have been determined from the previous cephalometric exam. These numbers are added or subtracted from the values measured on the model block to determine the new three-dimensional position of the maxillary cast.

The occlusal portion of the maxillary cast is removed from its base using a saw. As much plaster is removed from the cast as is necessary to accommodate the new position of the maxilla. If a fistula or edentulous gap is to be closed at the time of surgery, the maxillary cast can be cut into two pieces to simulate the arch compression that will be achieved at surgery. This also verifies that the new arch form articulates well with the mandibular occlusion. Soft wax is inserted in the gap between the base of the cast and the occlusal portion to allow slight manipulations while providing some stability. The tooth cusps are measured in three dimensions until they match the desired postoperative position of the maxilla. Once the model block verifies the maxilla is in its new position, the cast is secured to the mounting ring with sticky wax or plaster. Then it can be placed on the articulator to provide a mounting of the maxilla's postoperative position related to the mandible's preoperative position. An acrylic surgical splint is made at this

{AU: Chapter cross-reference OK ("Dental and Orthodontic Applications"?)}

1
2
3
4
5
6
7
8
9
10
11
12
13
14
15
16
17
18
19
20
21
22
23
24
25
26
27
28
29
30
31
32
33
34
35
36
37
38
39
40
41
42
43
44
45
46
47
48
49
L

point. In isolated maxillary surgery this splint will be the final splint; however, in two-jaw surgery it serves as the intermediate splint and will be used in the operating room to index the maxilla's new position to the mandible's preoperative position. For two-jaw surgery, a second mounting with the casts set at the desired occlusion is used to make a final splint that represents the new position of the mandible to the maxilla.

Patients who present with a cleft lip and/or palate anomaly have several anatomic differences compared with unaffected patients. The maxilla is typically deficient in both the anteroposterior and vertical dimensions. Because midface retrusion can be significant, it frequently appears that the mandible is prognathic, but true mandibular prognathia is rare. The apparent prognathia is relative secondary to the maxillary deficiency. Finally, because of lesser segment collapse, the dental midline is often deviated toward the cleft side.

Despite having undergone alveolar bone grafting, many of these patients have deficient or missing bone in the region of the alveolus. Persistent palatal fistulas may be present as well. The lateral incisor is frequently missing in these patients, and closure of this space must be taken into consideration at the time of treatment planning. Various options for prosthetic reconstruction of this edentulous space are described in Chapter 27. If a large fistula is present in the alveolus, modifications of the LeFort I procedure can be performed to facilitate a tension-free alveolar closure. These are discussed in the next section.

{AU: Chapter cross-reference OK ("Dental and Orthodontic Applications")?}

SURGICAL TECHNIQUE

Orthognathic surgery for patients with cleft lip/palate is similar to that for patients without clefts, except for several important modifications necessary to maintain blood supply and assist in fistula closure.

Efficiency makes orthognathic surgery go smoothly. The first step is to place the lidocaine with epinephrine before the patient is prepared. Instruments are ordered on the Mayo stand according to when they are to be used, and by the time the incision is ready to be made the epinephrine has produced the desired vasoconstrictive effect (*Fig. 29-1*). The preoperative vertical

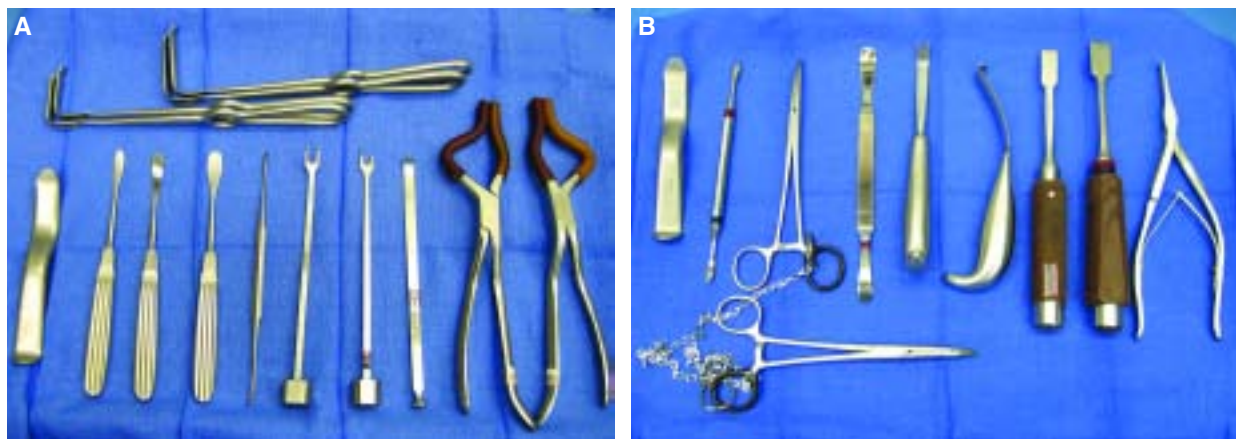

Fig. 29-1 **A**, Instruments for the maxillary procedure are placed on the tray after the mandibular cuts are made. **B**, The instruments for the sagittal split osteotomy are placed on the tray in the order in which they are to be used.

position of the maxilla is recorded by using a large caliper to measure the distance between the medial canthus of the right eye and the right central incisal edge. The technical steps of the LeFort I osteotomy are described in the following.

{AU: Could the first sentence of this paragraph be reworded as: Surgeons should avoid repeated use of each instrument as much as possible.}

→ Each instrument is used as much as possible before returning it to the nurse. With unilateral cleft lip patients, the standard incision can be made with little jeopardy to the premaxillary blood supply (*Fig. 29-2, A*). Each side of the cleft requires an incision made similar to that of an alveolar bone graft incision (*Fig. 29-2, B*). This allows for a two-layer closure of the palatal and nasal mucosa. If supplemental bone grafting is required at this time, harvested bone can be placed into the alveolar gap after fixation has been applied. If a wide fistula is present, the maxillary segments can be compressed to reduce the size of the alveolar space (*Fig. 29-2, C*). This maneuver ensures that the soft tissue closure is under minimal tension, and the chance of fistula closure is optimized. The canine may now be adjacent to the central incisor, but a restorative dentist can fabricate a prosthetic crown for the canine to make it look like a lateral incisor.

With patients who have bilateral clefts, care must be taken not to make the vestibular incision across the premaxilla. The premaxillary blood supply is from the vomer and the buccal mucosa. Because the vomer will be split, most of the blood flow to the premaxilla will be from the premaxillary buccal mucosa. A circumvestibular incision that violates this mucosa will severely jeopardize the blood supply of the premaxillary segment. To minimize the risk of complications, the incision is stopped just lateral to the alveolar cleft on each side (*Fig. 29-3, A*). Reflection of the mucosa from the premaxilla is minimized to preserve the blood supply. The osteotomy of the premaxillary segment is made from a posterior approach just anterior to the incisive foramen to allow mobilization of the segment without violation of the buccal mucosa (*Fig. 29-3, B*). Similar to a unilateral cleft maxilla, residual fistulae and inadequate alveolar bone may be present. If either is identified, it can be corrected by a two-layer mucosal closure and bone grafting into the alveolar defect (*Fig. 29-3, C*). If large gaps are present that may jeopardize fistula closure, the segments can be compressed at the alveolar gaps to reduce the tension of the repair (*Fig. 29-3, D*). Postoperative orthodontics and prosthetic restorations of the teeth can correct almost any postoperative dental aesthetic irregularities.

Once the incision is made, the mucosa is reflected in a subperiosteal plane to expose the piriform aperture, the zygomatic buttress, and the posterolateral maxilla (*Fig. 29-4, A*). A reciprocating saw is used to make a high LeFort I osteotomy in most cases. A high LeFort I osteotomy is cut horizontally in a lateral direct line from the piriform aperture to the zygomatic buttress. This line is taken as high as possible while staying at least 5 mm below the inferior orbital foramen. A vertical cut is made from the lateral edge of the horizontal cut and extended to an area about 5 mm above the tooth root apices. The lateral nasal walls are cut with a uniball osteotome and mallet. The vomer and septum can be reached through the lateral maxillary osteotomies, thereby preserving the mucosa. The pterygomaxillary junction can be separated with a 10-mm curved osteotome, or the maxillary tuberosity can be cut posterior to the last molar in the arch. The latter choice makes downfracture easier and results in fewer complications (*Fig. 29-4, B*).

Downfracture is completed using either digital pressure or Rowe disimpaction forceps. If a wide alveolar fistula is present, the greater and lesser segments can be compressed at the alveolus. The occlusion that would result from segment compression can be evaluated using dental casts during preoperative model surgery. Any deficiency of alveolar bone can be corrected with supplemental bone grafts after applying fixation, and fistulas can be corrected as well.

{AU: Sentence OK as edited?}

{AU: "26-gauge wire loops" OK?}

→ The surgical splint is placed to orient the new position of the maxilla to the mandible (*Fig. 29-4, C*). Maxillomandibular fixation is achieved using 26-gauge wire loops and arch bars, or the patient's braces, if present. It is extremely important to ensure the condyles are seated properly as the maxillomandibular complex is rotated to its new vertical position. Generally, patients with cleft lip/palate have vertical maxillary deficiency in addition to sagittal deficiency. This re-

1
2
3
4
5
6
7
8
9
10
11
12
13
14
15
16
17
18
19
20
21
22
23
24
25
26
27
28
29
30
31
32
33
34
35
36
37
38
39
40
41
42
43
44
45
46
47
48
49
L

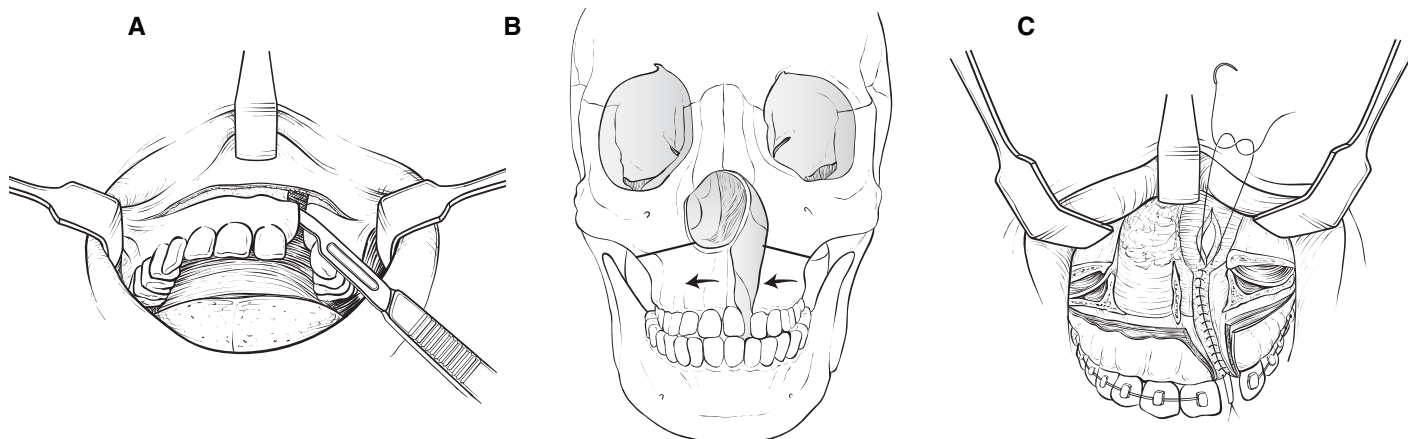


Fig. 29-2 **A**, For patients with a unilateral cleft lip, the incision is made similar to a standard LeFort I osteotomy, except an alveolar dissection is used if supplemental bone grafting or fistula closure is necessary. **B**, The LeFort osteotomy allows compression of the maxillary segments if necessary to close a preexisting fistula. **C**, Fistula repairs are easier after compression of the segments and exposure of nasal and palatal tissue.

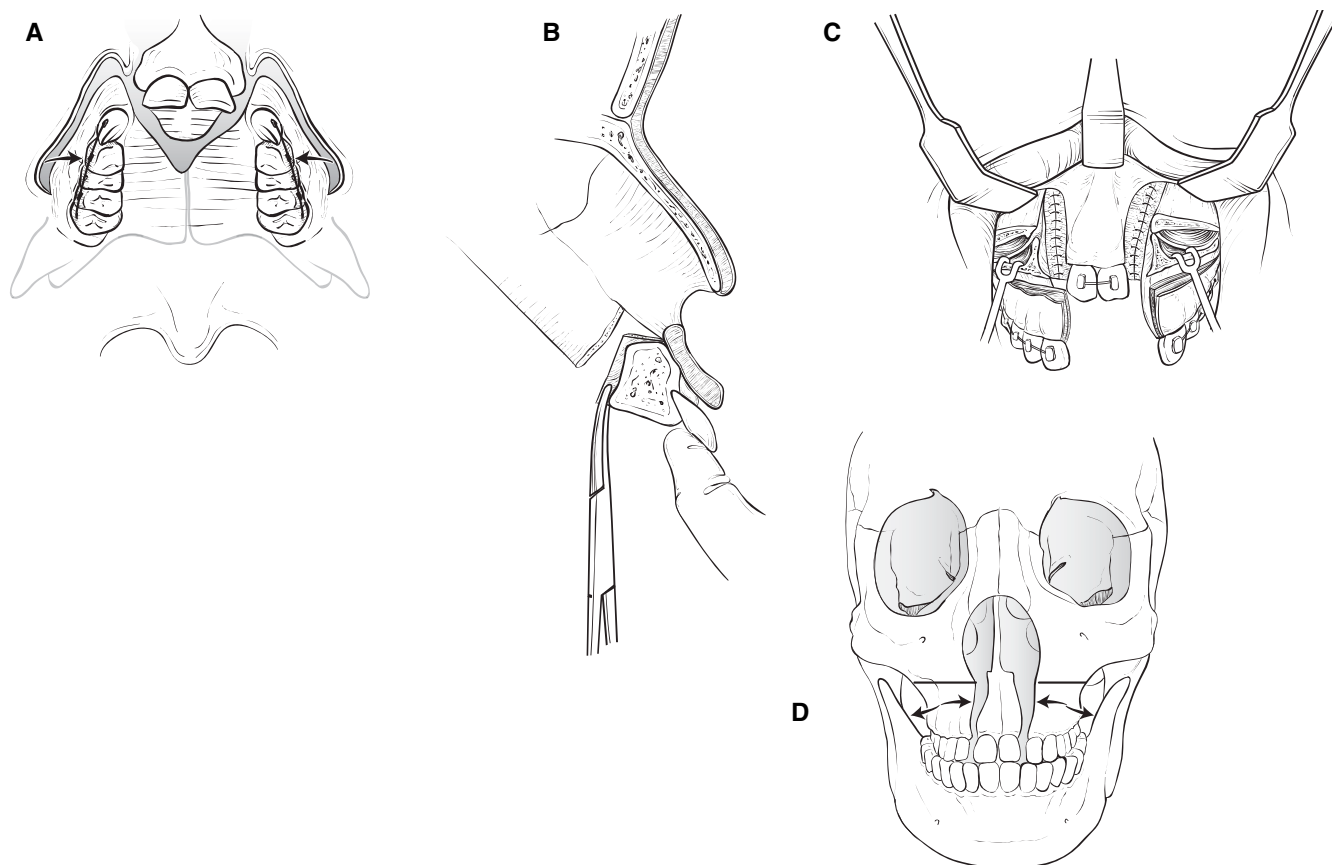
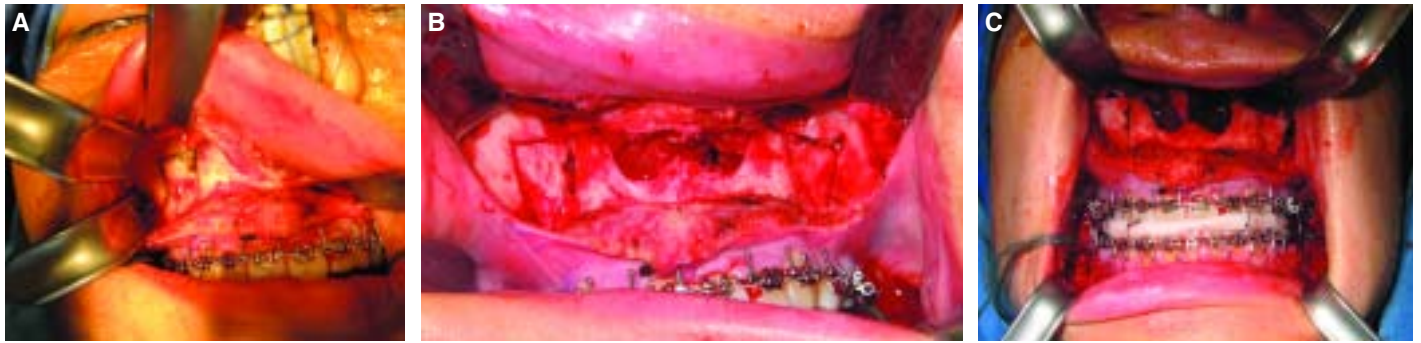


Fig. 29-3 **A**, For patients with a bilateral cleft, care is taken to avoid incisions across the premaxilla. **B**, The premaxillary osteotomy is completed from a posterior approach. **C**, Fistula repairs or supplemental bone grafting can be done at this time. **D**, Compression of the maxillary segments can be performed if wide fistulas are present.



{AUTHOR: Is ZMC spelled out correctly as zygomaticomaxillary complex?}

{AUTHOR: Please clarify: What does 3F-3H refer to?}

Fig. 29-4 **A**, Because cleft patients have maxillary deficiency, a high LeFort I osteotomy is preferred. The cuts extend laterally 5 mm below the inferior orbital nerve to the zygomaticomaxillary complex, and then vertically down before extending posterior to the molars. **B**, After the reciprocating saw has been used for osteotomy, osteotomes were used to separate the lateral nasal walls and septum, and cuts in the maxillary tuberosity were completed using a curved osteotome. **C**, The maxilla has been downfractured and secured to the mandible with the intermediate splint. Steps 3F-3H are now completed, and the final occlusion is established using either a final splint or the patient's natural occlusion.

quires the maxilla to be inferiorly positioned to its new position. If vertical lengthening greater than 5 mm is required, bone grafts are placed between the osteotomy segments to reduce relapse. Rigid fixation is used to secure the maxilla into its new position. If any instability remains across the maxillary segments, a small plate can be placed across the segments to reduce mobility and maintain the bone graft. Because an osteotomized cleft maxilla results in a multisegment maxilla, the surgical splints are wired in place for 6 to 8 weeks to allow bone healing.

If two-jaw surgery is to be performed, the mandibular cuts are made first, but the split is not undertaken until the maxilla has been plated. A bilateral sagittal split osteotomy is then performed as described in the following.

{AUTHOR: Please clarify: What is tied to the mouth prop? the tongue or the retractor?}

A Sweetheart retractor is placed to retract the tongue and is tied with a sponge to the mouth prop. An incision is made from the point where the ramus meets the external oblique ridge anteriorly to the first molar (**Fig. 29-5, A**). The tissue is dissected off the anterior ramus up to the top of the coronoid process. A Kocher with a chain is clamped to the tip of the coronoid process. The chain is secured to the head drape to pull the Kocher toward the patient's head in a superior direction. The clamped Kocher serves as a retractor for the intraoral mucosa.

{AU: What type of instrument is the Kocher—a clamp or a forceps?}

The remaining mucosa and tissue are reflected from the medial ramus and external oblique ridge. A Seldin retractor is placed medial to the ramus and turned 60 degrees so the inferior edge of the retractor is lateral to the superior edge, thus exposing the medial ramus for the osteotomy. As the Seldin is moved inferiorly it has a natural stop, the lingula, which is just above the point where the inferior alveolar nerve enters the mandibular foramen (**Fig. 29-5, B**). A reciprocating saw is then placed about two thirds of the distance to the posterior edge of the ramus, and a medial cut is made into cancellous bone. Once the medial cut is complete the osteotomy is extended down the anterior portion of the ramus just through the cortical bone. This cut follows the external oblique ridge to the inferior border of the mandible (**Fig. 29-5, C and D**). Osteotomes are used along the osteotomy site, hugging the inner aspect of the outer cortex to minimize injury to the inferior alveolar nerve. A Smith spreader can also be used to free any residual areas of cancellous bone (**Fig. 29-5, E through G**).

1
2
3
4
5
6
7
8
9
10
11
12
13
14
15
16
17
18
19
20
21
22
23
24
25
26
27
28
29
30
31
32
33
34
35
36
37
38
39
40
41
42
43
44
45
46
47
48
49
L

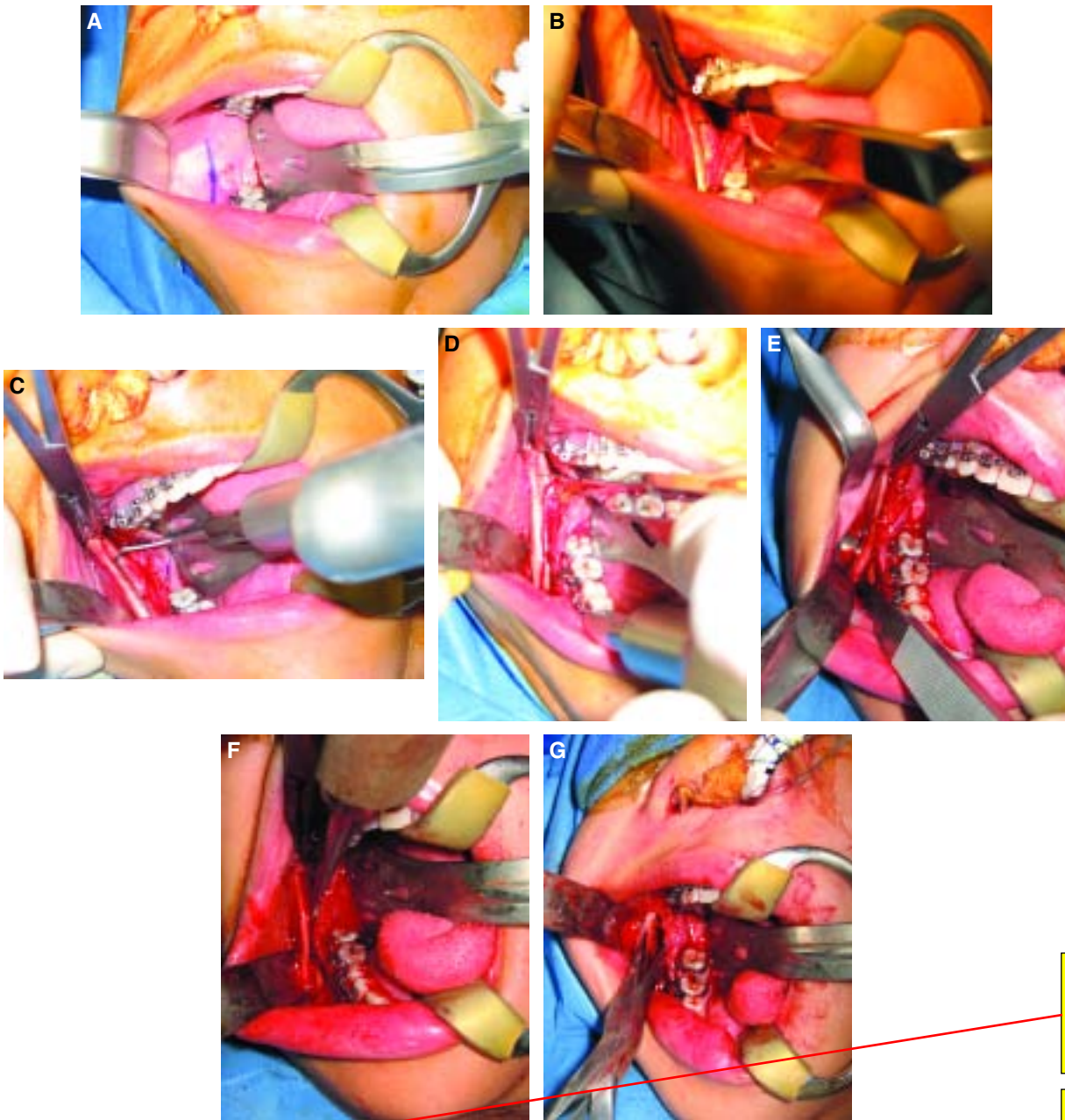


Fig. 29-5 **A**, An incision is made leaving enough medial mucosa for a secure closure at the conclusion of the procedure. A hinged mouth prop is placed in the opposite side of the mouth, and a sponge is used to secure this to the end of the tongue retractor. **B**, A curved Kocher with a chain is placed on the coronoid process and the chain is secured to the head drape. A mandibular body retractor is placed lateral to the angle, and a Seldin retractor is placed medial to the ramus and above the lingula, thus protecting the nerve. **C**, The osteotomy is made with a reciprocating saw and is a continuous cut through only cortical bone from the medial ramus to the inferior border of the mandible along the external oblique ridge. **D**, The osteotomy is shown after completion. **E**, The remaining steps are usually completed after the LeFort is plated in two-jaw surgery. A small osteotome is used to verify that cuts are complete. **F**, A larger fiber-handled osteotome is used to apply gradual pressure to initiate the split. **G**, A Smith spreader can be used to complete the split. The nerve is checked to make sure it is in the distal segment before wide separation of the segments.

{AUTHOR: Please clarify: At what point in the procedure does Fig. 29 occur?}

{AU: Fig 29-5B See previous queries regarding Kocher}

{AU: Fig 29-5B Please clarify: Which angle?}

{AUTHOR: In the legend for Fig. 29-5, B and G, which nerve is referred to—the inferior alveolar?}

1
2
3
4
5
6
7
8
9
10
11
12
13
14
15
16
17
18
19
20
21
22
23
24
25
26
27
28
29
30
31
32
33
34
35
36
37
38
39
40
41
42
43
44
45
46
47
48
49
L

Once the osteotomy is complete, the distal segment is moved into the desired position either with the final surgical splint or without a splint if the desired occlusion can be achieved by placing the jaws into maximal intercuspal position. Maxillomandibular fixation is again applied to secure the new position of the mandible to the new position of the maxilla. The distal portion of the proximal mandibular segment is grasped using a Kocher and is used to seat the condyle and align the segments into the desired position. When the position is achieved, a second Kocher is positioned to hold the proximal and distal segments together, maintaining the new position of the mandibular segments while fixation is secured.

A transbuccal trochar is used to allow percutaneous placement of fixation screws. A mosquito hemostat is placed inside the mouth near the area of desired screw placement. This is pal-

{AU: See previous query. What is a Kocher?}

{AUTHOR: What is being used to seat the condyle? The mandibular segment or the Kocher?}

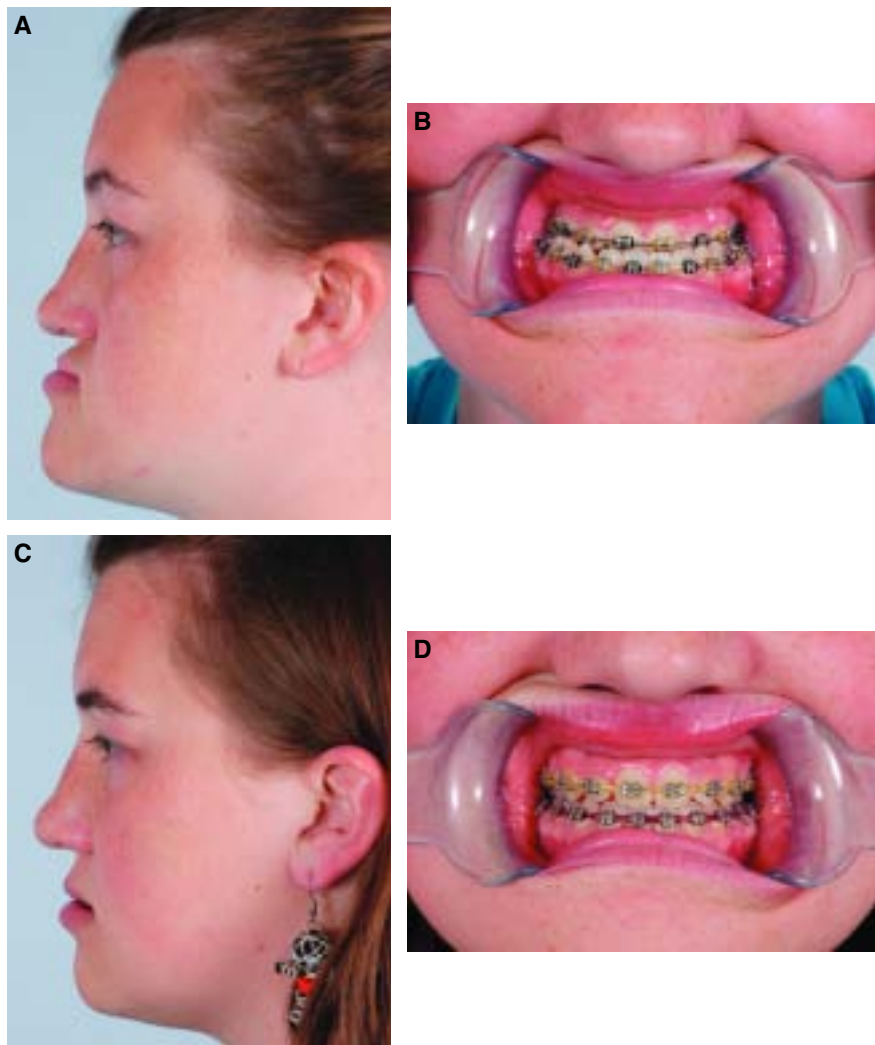


Fig. 29-6 A, Preoperative appearance of a patient with a unilateral cleft before LeFort I advancement and bilateral, sagittal split, posterior positioning of the mandible. B, Preoperative occlusion. C, The patient is shown postoperatively. D, Postoperative occlusion.

{AU: Does A read OK as edited?}

{AU: How long postoperatively?}

1
2
3
4
5
6
7
8
9
10
11
12
13
14
15
16
17
18
19
20
21
22
23
24
25
26
27
28
29
30
31
32
33
34
35
36
37
38
39
40
41
42
43
44
45
46
47
48
49
L

1 palpated on the cutaneous surface, and a small stab incision is made through which the trocar is in-
 2 troduced into the oral cavity. A cheek retractor is attached to the trocar, and three screws are
 3 placed at the superior edge of the mandible in the region of overlapping bone. The surgeon
 4 should feel resistance as the outer cortex of the proximal segment is drilled, a loss of resistance
 5 as the cancellous bone is entered, and a second area of resistance as the inner cortex of the dis-
 6 tal segment is encountered.

7 Once both sides are completed, intermaxillary fixation is released and the final occlusion is
 8 verified (**Fig. 29-6, A through D**). If the occlusion is not in the desired position, the screws are
 9 removed and the process is repeated. Typically, if the desired occlusion is not achieved, it is be-
 10 cause the condyle was not properly seated during application of fixation.

12 ORTHOGNATHIC SURGERY AND VELOPHARYNGEAL 13 INSUFFICIENCY/SPEECH

14 It is generally accepted that velopharyngeal insufficiency (VPI) in patients with cleft lip/palate is
 15 caused by malalignment or shortening of the palatal musculature, skeletal growth and develop-
 16 ment, and/or surgical sequela that can lead to abnormal structural relationships. Alveolar fistu-
 17 las and a constricted arch can contribute to resonance disorders (hypernasality or hyponasality)
 18 or articulation defects (errors in formation of consonants). Given the intricate attachment of the
 19 maxilla to the muscular apparatus of the velum, it follows that moving the maxilla can change
 20 velopharyngeal function.

21 Janulewicz et al² performed a retrospective study of the change in velopharyngeal function
 22 in 54 cleft lip and palate patients who underwent maxillary advancement with or without a
 23 mandibular set-back procedure over a 21-year period. As summarized in **Table 29-1**, their study

{AUTHOR: What is palpated? The hemostat or the area of desired placement?}

24 **Table 29-1 Comparison of Preoperative and Postoperative Speech Variables**

25	26	27
28	Preoperative Evaluation	Postoperative Evaluation
29	% (n)	% (n)
30		
31	Total Number of Patients: 54	
32	VP function: competent	42 (23)
33	VP function: borderline competent	36 (20)
34	VP function: borderline incompetent	9 (5)
35	VP function: complete VPI	13 (7)
36	Normal nasality	40 (22)
37	Mild hypernasality	18 (10)
38	Moderate hypernasality	4 (2)
39	Severe hypernasality	2 (1)
40	Hyponasality	33 (18)
41	Reduced sibilant IOAP	26 (14)
42	Reduced fricative IOAP	16 (9)
43	Reduced plosive IOAP	6 (3)
44	Anterior dentition errors	64 (35)
45	Mean speech score	2.46
46		4.24

47 *IOAP*, Intraoral air pressure; *VP*, Velopharyngeal; *VPI*, Velopharyngeal incompetence.

1
2
3
4
5
6
7
8
9
10
11
12
13
14
15
16
17
18
19
20
21
22
23
24
25
26
27
28
29
30
31
32
33
34
35
36
37
38
39
40
41
42
43
44
45
46
47
48
49
L

shows a decline in competent velopharyngeal function (42% to 18%) and an increase in both borderline incompetence (9% to 22%) and complete VPI (13% to 20%). The authors also note that the quality of speech declined, as evidenced by the increase in overall objective speech score from 2.46 to 4.24 (the higher the score, the worse the speech). In contrast, the authors noted that articulation defects improved, although the improvements did not achieve statistical significance. Preoperatively 84% (46 patients) had at least one articulation defect compared with 73% (40 patients) postoperatively.

Other published studies have shown similar results or no change in VPI function. Both Watzke et al³ and, more recently, Phillips et al⁴ have shown that the extent of anteroposterior maxilla movement is unrelated to velopharyngeal deterioration and is not a useful predictor. In a study of 26 patients (16 unilateral complete and 9 bilateral complete cleft lips and palates), they showed that all patients who had perceived hypernasal speech preoperatively had hypernasality after advancement. Furthermore, 9 of 12 patients (75%) who had preoperative nasopharyngoscopy showing borderline or inadequate closure developed VPI postoperatively. Furthermore, they found that nasoendoscopy adds little to perceived speech testing in its ability to predict which patients develop velopharyngeal incompetence after maxillary advancement. Based on these results, the researchers concluded that preoperative assessment can predict postoperative speech and velopharyngeal function and that nasoendoscopy plays a minor role in preoperative evaluation for patients without fistulas and borderline or hypernasal speech.

Because elements of speech are linked to hard and soft tissue relationships, advancing the maxilla would seemingly affect articulation; however, data from published studies appear to be inconsistent. Witzel et al showed that improving skeletal malocclusions with orthognathic surgery improved articulation, especially for the production of sibilant sounds. In contrast, Dalton et al found no improvement in articulation after surgery.

In summary, it appears that although a positive effect on articulation might be achieved by orthognathic surgery, it might be at the expense of velopharyngeal function. Further prospective controlled studies would be helpful for discovering the relationships between maxillary advancement and speech. Because there is uncertainty about how much maxillary advancement might affect speech, the physician should discuss the possibilities with the patient and family before surgery.

SKELETAL STABILITY AND RELAPSE

Posnick et al⁵ performed a retrospective study evaluating relapse in patients who had undergone orthognathic surgery for cleft lip/palate between 1987 and 1990. They found that there was no significant difference in outcome between patients who had maxillary surgery alone and those who had operations on both jaws. Furthermore, the outcome did not vary significantly with the type of autogenous bone graft used or the segmentalization of the osteotomy.

All 35 patients included in the study had undergone a modified LeFort I maxillary osteotomy with varied degrees of horizontal advancement, transverse arch widening, and vertical change. Eleven of the 35 patients (32%) also required mandibular surgery consisting of sagittal split osteotomies. In 13 of 35 patients (37%) a pharyngoplasty was in place at the time of maxillary LeFort I osteotomy.

The results of the study are summarized in *Table 29-2*. The mean horizontal advancement achieved for the group was 6.9 ± 2.6 mm at 1 week; 5.3 ± 2.7 mm was maintained 1 year later (mean relapse 1.6 mm). In 11 of 35 patients (32%) the relapse was less than 1.0 mm. For the 13 patients (37%) who had pharyngoplasty at the time of the LeFort I osteotomy, the mean hor-

{AU: Should 84% be changed to 85%, and 73% be changed to 74%? $46/54 = 0.8519$ & $40/54 = 0.7407$.}

{AU: Did Phillips et al study 25 or 26 patients? 16 unilateral complete + 9 bilateral complete = 25.}

{AUTHOR: OK to insert "postoperatively" here?}

{AU: There is no reference for Witzel et al at the end of the chapter. Please supply. Does this refer to the suggested reading: Witzel MA, Munro IR. Velopharyngeal insufficiency after maxillary advancement. *Cleft Plate J* 14:176-180, 1977?}

{AUTHOR: Please include a ref for Dalton et al.}

1
2
3
4
5
6
7
8
9
10
11
12
13
14
15
16
17
18
19
20
21
22
23
24
25
26
27
28
29
30
31
32
33
34
35
36
37
38
39
40
41
42
43
44
45
46
47
48
49
L

Table 29-2 Patients with Unilateral Cleft Lip/Palate Undergoing LeFort I Osteotomy With Miniplate Fixation: Mean Horizontal and Vertical Displacement and Relapse

Time After Surgery	Effective Horizontal Mean Advancement (mm)	Effective Vertical Mean Change (mm)
1 week	6.9 ± 2.6	2.1 ± 2.4
6-8 weeks	6.3 ± 2.6	1.9 ± 2.1
1 year	5.3 ± 2.7	1.7 ± 2.0

horizontal advancement was 8.2 mm immediately after the operation and 6.5 mm 1 year later. Stability of the vertical displacement was also evaluated. No maxillary vertical change was necessary in 12 of 35 (34%) patients. The mean vertical displacement of the maxilla in patients who underwent vertical repositioning was 2.1 ± 2.4 mm at 1 week; 1.7 ± 2.0 mm was maintained 1 year later. The authors concluded that neither horizontal nor vertical relapse was related to the extent of movement. Overjet seen in cephalometric radiographs 1 year postoperatively was maintained in all patients, whereas a positive overbite was maintained in only 30 of 35 patients (85%).

{AUTHOR: Should 85% be rounded up to 86%?}

Other investigators have found a correlation between relapse and the degree of advancement.⁶ To identify factors associated with relapse after orthognathic surgery in patients with cleft lip/palate, Hirano et al⁷ performed a retrospective study on 58 patients with cleft lip/palate who underwent orthognathic surgery over a 10-year period. They identified the following factors related to relapse:

1. Horizontal advancement. The mean horizontal relapse was 24.1% of the mean advancement. There was significant correlation between extent of the relapse and advancement. The authors report that complete surgical mobilization of the maxilla is important for preventing relapse.
2. Vertical displacement (inferior positioning). The mean inferior vertical elongation was 3 mm with a relapse of 2.1 mm. The authors recommend a 2 mm overcorrection with inferior positioning of the maxilla.
3. Rotation—clockwise or counterclockwise. Most surgical rotation was lost, and relapse was seen with both clockwise and counterclockwise rotations. The authors suggest overcorrection to mitigate the effects of relapse.
4. Type of cleft. Orthognathic surgery for a bilateral cleft was more likely to result in relapse. The authors attribute this greater likelihood to increased scarring of palatal tissues and multiple missing teeth.
5. Previous alveolar bone grafting. Although studies have reported the value of alveolar bone grafting for establishing advancement stability and minimizing relapse, the study by Hirano et al⁷ found no association between alveolar bone graft and the rate of relapse in patients with unilateral cleft lip/palate.
6. Number of missing teeth. No correlation was found between the number of missing teeth and relapse, although the authors stress that multiple missing teeth can compromise the stability of the occlusion.
7. Type of orthognathic surgery. There was no difference in the relapse rate between patients who underwent maxillary surgery alone and those who underwent two-jaw surgery.

{AUTHOR: In 1 Meaning OK as edited?}

{AUTHOR: Please verify. In 6 You say there is no correlation between number of missing teeth and relapse. In 4 you attribute a greater relapse rate to multiple missing teeth.}

1
2
3
4
5
6
7
8
9
10
11
12
13
14
15
16
17
18
19
20
21
22
23
24
25
26
27
28
29
30
31
32
33
34
35
36
37
38
39
40
41
42
43
44
45
46
47
48
49
L

ALTERNATIVES TO ORTHOGNATHIC SURGERY

Advancement by External Distraction Osteogenesis

Patients with mild to moderate maxillary hypoplasia are good candidates for traditional orthognathic surgery; however, those with severe maxillary retrusion (greater than 10 mm) are prone to a significant amount of relapse. Several studies have shown that patients with severe maxillary deficiency have less predictable results and a higher rate of relapse. Furthermore, the need for revision and prolonged orthodontics is higher. This subset of patients might benefit from advancement by distraction osteogenesis.

{AU: Please provide references for the several studies that have shown patients with severe maxillary deficiency are prone to results that are less predictable and have a higher rate of relapse.}

Distraction osteogenesis at the LeFort I level has been recommended for early treatment of severe midface deficiency for patients in the mixed dentition stage. Cho and Kyung⁸ conducted a retrospective study to evaluate the long-term stability of maxillary distraction osteogenesis using a rigid external device, based on a 7-year experience. In their study, the mean distraction length was 13.6 mm immediately after distraction (**Table 29-3**). However, at the 6-month follow-up the mean distraction length was 10.8 mm, and 10.4 mm at the 1- to 6-year follow-up. Based on their results, the mean postoperative relapse rate was 23% at 1 to 6 years. Preoperatively the mean SNA angle was 78.5 degrees and immediately after distraction it was 90.7 degrees. Six months postoperatively the mean SNA angle was 87.2 degrees, and it was 86.9 degrees 1 to 5 years postoperatively. These results demonstrate that most relapse occurs in the first 6 months. The relapse rate increased up to 6 months after distraction and was not statistically significant between 1 year and 6 years after distraction. They concluded that a 20% to 30% overcorrection is required with maxillary advancement to compensate for the relapse.

{AUTHOR: Please spell out SNA.}

The results published by Cho and Kyung⁸ contrast with the results published by Polley and Figuerua⁹ in which 16 patients between 5 and 25 years of age underwent correction of maxillary hypoplasia using external distraction. The patients underwent distraction followed by a 2- to 3-week rigid retention phase and achieved a mean advancement of 11.7 mm. The authors reported no relapse at the 4- and 12-month follow-up periods. In later reports they attributed decreased facial convexity at the 1-year follow-up to a combination of maxillary resorption, forward mandibular growth, and closed rotation of the mandible.

The benefits of rigid external distraction are the versatility and flexibility of both the amount and the direction of the distraction process. With a skull-anchored, external-head-frame distractor attached to an orthodontic splint, precise control of the maxillary segments can be achieved with accurate, consistent, and unlimited distraction. However, the only aspect of this system that is rigid is the halo, which attaches to the head. The maxilla is not rigidly held in its postoperative position after advancement. Patients are allowed to function with an osteotomized maxilla. Although studies have not shown a higher incidence of nonunion with this concept, it contradicts principles of fracture management.

Table 29-3 External Distraction Outcomes

	Immediate Postoperative Outcome	6 Months Postoperatively	1 to 6 years Postoperatively
Mean length	13.6 mm	10.8 mm	10.4 mm
Mean relapse rate		20.7%	23.0%

Advancement by Internal Distraction Osteogenesis

Kumar et al¹⁰ compared the correction of severe maxillary retrusion using distraction against conventional orthognathic surgery. Fifty-one patients with cleft lip/palate were divided into three groups based on extent of maxillary retrusion and type of orthognathic treatment:

Group 1 (n = 20): mild to moderate deficiency (10 mm or less) treated with a conventional orthognathic procedure

Group 2 (n = 11): severe deficiency (10 mm or more) treated with conventional orthognathic surgery

Group 3 (n = 20): severe deficiency (10 mm or more) treated with distraction osteogenesis

The results showed that group 1 patients had a mean advancement of 7 mm (Table 29-4). In this group, all patients finished with a class I occlusion and had no complications, relapse, or revisions. Group 2 patients had a mean horizontal advancement of 11 mm. In this group, one patient (9%) had a class III malocclusion postoperatively, and six of 11 patients (55%) had class III malocclusion at follow-up. Seven of 11 (64%) developed relapse, and five of 11 (45%) underwent reoperation. Group 3 patients had a mean advancement of 25 mm. At follow-up, a 15% relapse rate was noted (three of 20 patients).

Although group 2 patients underwent less advancement than group 3 patients, group 2 patients had a higher relapse rate. The authors suggest that the gradual skeletal advancement offered by distraction provides greater advancement with less relapse in patients with severe maxillary deficiency. The cicatricial retraction used for group 2 patients most likely contributed to the high relapse rates seen in this group. The authors also suggest that gradual advancement with distraction osteogenesis allows the LeFort I segment to move a greater distance and remain stable in its new location because of slow scar tissue adaptation.

{AU: Please clarify: Did patients with exactly 10 mm of deficiency go into Group 1 or Group 2?}

{AU: How long postoperatively was the follow-up conducted?}

{AUTHOR: Please clarify: Do you mean yourselves, or Kumar et al?}

{AUTHOR: Meaning OK as edited?}

Table 29-4 Orthognathic Outcome

	Group I Mild-Moderate Deficiency	Group II Severe Deficiency	Group III Severe Deficiency
Deficiency	≤10 mm	≥10 mm	≥10 mm
Number of patients	20	11	20
Type of procedure	Orthognathic surgery	Orthognathic surgery	Internal distraction
Mean advancement	7 mm	11 mm	25 mm
ΔX preoperative to postoperative	5 mm	7.22 mm	16.5 mm
ΔX postoperative to follow-up	4.9 mm	5.8 mm	16.1 mm
ΔY preoperative to postoperative	-0.5 mm	-0.4 mm	-1.1 mm
ΔY postoperative to follow-up	-0.5 mm	-0.2 mm	-1.0 mm
No. of relapse patients	0	7	3
Relapse rate	0%	64% (7/11)	15% (3/20)

ΔX Postoperative to follow-up, horizontal change from postoperative to follow-up; ΔX preoperative to postoperative, horizontal change from preoperative to postoperative; ΔY postoperative to follow-up, vertical change from postoperative to follow-up; ΔY preoperative to postoperative, vertical change from preoperative to postoperative.

Effects on speech were compared between distraction and orthognathic procedures. Patients who underwent distraction showed better speech scores and less VPI than acutely advanced patients. Furthermore, nasal endoscopy in select patients showed that the patients who underwent distraction had fewer structural problems with oronasal closure than patients in the orthognathic group.

This study indicates that for patients with severe maxillary deficiency, LeFort I distraction may offer improved results compared with traditional orthognathic surgery. It is the surgeon's choice to determine what will give the patient the best result given the surgeon's comfort with techniques of distraction osteogenesis and orthognathic surgery.

Orthognathic surgery is typically performed after skeletal growth is complete so that the patient's mandible does not outgrow the surgical correction achieved by maxillary advancement. Delaying the procedure also avoids the risk of injuring tooth buds or roots of the permanent dentition if the teeth have not erupted beyond the site of the planned osteotomy. The benefit of the traditional orthognathic surgical procedure is precise control of the occlusion and application of rigid fixation to secure the maxilla's position.

Unlike the one-stage orthognathic procedure, advancement by distraction requires at least two operative procedures. The patient must also endure the appliance for 8 to 12 weeks. The LeFort I osteotomy for distraction is essentially the same as that performed for traditional orthognathic surgery, so the risk of injury to tooth buds as well as the potential to outgrow the correction are the same. Also, if distraction is performed at an earlier stage, the risks are higher than with traditional orthognathic surgery. Final control of occlusion is not as precise with internal distraction, and mobility is present after external distraction. Surgical distraction must offer clear benefits over traditional orthognathic surgery to be considered for treatment. Indications for using maxillary distraction over traditional orthognathic surgery are reduced rates of relapse and VPI. With an extremely deficient maxilla for which the surgeon is not comfortable with his or her ability to achieve adequate advancement using orthognathic techniques, distraction does allow a slow adaptation of the scarred palatal tissues, possibly reducing relapse. Additionally, distraction has been shown to have a lower postoperative incidence of VPI in some studies.

Unless distraction achieves perfect occlusion without relapse and mandibular overgrowth, the patient will still require subsequent orthognathic surgery. In this situation the question arises as to whether the long process of distraction osteogenesis followed by an orthognathic procedure offers any advantages over two-stage LeFort I osteotomies. It is our opinion that although distraction osteogenesis is a valuable tool, its indications must be carefully weighed against those of traditional orthognathic techniques.

CONCLUSIONS

Orthognathic surgery is one of the most effective treatment modalities for dentofacial deformities in patients with a cleft lip and/or palate anomaly. A review of the literature has shown that the operation can be performed safely. The benefits of the surgery, such as enhanced aesthetics and optimal occlusion, must be balanced by the functional outcomes such as a possible deterioration of speech patterns and a potential for other complications. Correction of maxillary hypoplasia by distraction osteogenesis, either internal or external, is an alternative to consider—especially for patients with severe maxillary hypoplasia. The most important aspect of managing these patients is that each surgeon ultimately chooses the techniques with which he or she feels comfortable to achieve the best result for the patient.

{AUTHOR: Do you mean "stage" or "age" here?}

{AUTHOR: Please provide references to support this statement: "Additionally...so me studies."}

1
2
3
4
5
6
7
8
9
10
11
12
13
14
15
16
17
18
19
20
21
22
23
24
25
26
27
28
29
30
31
32
33
34
35
36
37
38
39
40
41
42
43
44
45
46
47
48
49
L

KEY POINTS

- Dentofacial deformities, in particular maxillary retrusion resulting in class II malocclusion, are typical in the cleft lip and palate population. Of patients in this group, 25% to 30% have severe enough midface retrusion to require orthognathic surgery.
- The cause of maxillary hypoplasia remains unclear. Some evidence supports the fact that inelasticity of scar tissue restricts facial growth and suggests an intrinsic growth deficiency that is unrelated to surgery.
- Team management of patients with cleft lip/palate is essential to ensure that all cleft-related issues are addressed when planning surgery and that procedures are optimally timed.
- The orthodontist's role in preoperative treatment, assessment, and operative planning is critical.
- Because maxillary advancement may affect both velopharyngeal function and articulation, a complete speech evaluation before the surgery, including videonasendoscopy, helps to prepare both the surgeon and patient for possible postoperative changes.
- Although orthognathic surgery appears to have a positive effect on articulation, it may be at the expense of velopharyngeal function.
- The maxilla is typically deficient in both anteroposterior and vertical dimensions. Because midface retrusion can be significant, it frequently appears that the mandible is prognathic; however, true mandibular prognathia is rare.
- Orthognathic surgery should ideally be performed after facial growth is complete. If surgery is performed earlier, the likelihood is high that additional (though possibly less complicated) surgery may be required when the patient reaches skeletal maturity.
- Orthognathic surgery for patients with cleft lip/palate is similar to that performed for patients without a cleft deformity. However, several important modifications are necessary to maintain blood supply and assist with fistula closure.
- A LeFort I osteotomy, in its varied and modified forms, is the workhorse procedure for treating maxillary retrusion associated with cleft lip and palate. It may be performed as the only procedure or in combination with mandibular surgery, depending on the requirements of the patient.

Continued

1
2
3
4
5
6
7
8
9
10
11
12
13
14
15
16
17
18
19
20
21
22
23
24
25
26
27
28
29
30
31
32
33
34
35
36
37
38
39
40
41
42
43
44
45
46
47
48
49
L

KEY POINTS

(continued)

- For patients with a bilateral cleft, care must be taken to avoid making the vestibular incision across the premaxilla. Premaxillary blood is supplied by the vomer and the buccal mucosa. Because the vomer will be split, most of the blood flow to the premaxilla will be from the premaxillary buccal mucosa. A circumvestibular incision that violates this mucosa will severely jeopardize the blood supply of the premaxillary segment.
- If a wide alveolar fistula is present, the greater and lesser segments can be compressed at the alveolus. The occlusion that would result from segment compression should be evaluated on dental casts during preoperative model surgery. Any deficiency of alveolar bone can be corrected with supplemental bone grafts after applying fixation, and any residual fistulas can also be corrected at this time.
- If two-jaw surgery is to be performed, the mandibular cuts are made first, but the split is not undertaken until the maxilla has been plated.
- A surgical splint, fashioned during surgical planning, is essential to orient the new position of the maxilla to the mandible.
- It is extremely important to ensure the condyles are seated as the maxillo-mandibular complex is rotated to its new vertical position.
- Postoperative orthodontics and prosthetic restorations of the teeth can correct almost all postoperative dental aesthetic irregularities.
- The stability of a maxillary advancement is related to the extent of movement and the type of cleft, with a greater rate of relapse noted in cases of bilateral cleft lip and palate. This result may relate to more scarring in these patients.
- Although patients with mild to moderate maxillary hypoplasia are good candidates for traditional orthognathic surgery, those with severe maxillary retrusion (greater than 10 mm) are prone to a significant relapse. This subset of patients might benefit from advancement by distraction osteogenesis.

1
2
3
4
5
6
7
8
9
10
11
12
13
14
15
16
17
18
19
20
21
22
23
24
25
26
27
28
29
30
31
32
33
34
35
36
37
38
39
40
41
42
43
44
45
46
47
48
49
L

REFERENCES—With Key Annotated References

1. Weinzweig J, Panter KE, Seki J, et al. The cleft palate: IV. Midfacial growth and bony palatal development following in utero and neonatal repair of the congenital caprine model. *Plast reconstr surg* 118:81-93, 2006.
2. Janulewicz J, Costello BJ, Buckley MJ, et al. The effects of Le Fort I osteotomies on velopharyngeal and speech functions in cleft patients. *J Oral Maxillofac Surg* 62:308-314, 2004.
This article details a retrospective study from the University of Pittsburgh on the effects of orthognathic surgery on velopharyngeal and speech functions. The study objectively and subjectively evaluates the quality of speech in 54 patients who underwent orthognathic surgery between 1981 and 2004.
3. Watzke I, Turvey TA, Warren DW, et al. Alterations in velopharyngeal function after maxillary advancement in cleft palate patients. *J Oral Maxillofac Surg* 48:685-689, 1990.
4. Phillips, JH, Klaiman P, Delorey R, et al. Predictors of velopharyngeal insufficiency in cleft palate orthognathic surgery. *Plast Reconstr Surg* 115:681-686, 2005.
This article is a retrospective study from the Hospital for Sick Children and others in Canada that includes 26 patients who underwent orthognathic advancement. Assessments of speech and velopharyngeal function before and after orthognathic surgery and the role of nasopharyngoscopy are detailed.
5. Posnick JC, et al. Cleft-orthognathic surgery: the unilateral cleft lip and palate deformity. In Craniofacial and Maxillofacial Surgery in Children and Young Adults. Philadelphia: WB Saunders, 2001.
In this comprehensive chapter, the author provides a detailed description of his surgical technique in the unilateral cleft patient including his preoperative evaluation and results for 45 patients who underwent LeFort I maxillary osteotomy.
6. Heliovaara A, Ranta R, Hukki J, et al. Skeletal stability of Le Fort I osteotomy in patients with isolated cleft palate and bilateral cleft lip and palate. *Int J Oral Maxillofac Surg* 31:358-363, 2002.
This article from Helsinki, Finland retrospectively evaluates the skeletal stability and relapse rate of 25 patients who underwent correction of maxillary hypoplasia via orthognathic surgery. Fourteen patients had isolated cleft palate (mean age 27.2 years) and 11 patients had bilateral cleft lip and palate (mean age 23.7 years). The authors evaluate surgical advancement and relapse in both the horizontal and vertical dimensions.
7. Hirano A, Suzuki H. Factors related to relapse after Le Fort I maxillary advancement osteotomy in patients with cleft lip and palate. *Cleft Palate Craniofac J* 38:1-10, 2001.
This article from Nagasaki University School of Medicine in Japan is a retrospective study of 58 patients (42 unilateral cleft lip/palate and 16 bilateral cleft lip/palate) who underwent orthognathic surgery to correct maxillary hypoplasia. The authors report a mean follow-up period of 2½ years. Based on cephalometric and statistical analyses, the authors elucidate factors related to relapse after bilateral sagittal split osteotomy.
8. Cho BC, Kyung HM. Distraction osteogenesis of the hypoplastic midface using a rigid external distraction system: the results of a one- to six-year follow-up. *Plast Reconstr Surg* 118:1201-1212, 2006.
This article reports the authors' experience at Kyungpook National University in Korea using external distraction to correct severe maxillary hypoplasia. They present results of nine patients and include the advantages and disadvantages of their procedure.
9. Polley JW, Figueroa AA. Rigid external distraction: its application in cleft maxillary deformities. *Plast Reconstr Surg* 102:1360-1372, 1998.
10. Kumar A, Gabbay JS, Nikjoo R, et al. Improved outcomes in cleft patients with severe maxillary deficiency after Le Fort I internal distraction. *Plast Reconstr Surg* 117:1499-1509, 2006.
This article reports the authors' experience at the University of California, Los Angeles, using internal distraction to correct severe maxillary hypoplasia. They present a comparative analysis of 51 patients who underwent correction of maxillary deficiency by LeFort I osteotomy and advancement by a conventional orthognathic procedure and by internal distraction.

{AU: Please provide the names of Dr. Posnick's coauthors in reference 5.}

{AU: Is BSSO spelled out correctly?}

SUGGESTED READINGS

- Baker SB. Orthognathic surgery. Grabb & Smith's Plastic Surgery, 6th ed. Philadelphia: Lippincott Williams & Wilkins, 2007.
- Bauman A. Importance of soft tissue for skeletal stability in maxillary advancement in patients with cleft lip and palate. *Cleft Palate Craniofac J* 40:65-70, 2003.
- Bell WH, Levy BM. Revascularization and bone healing after anterior maxillary osteotomy. *J Oral Surg* 27:249-255, 1969.
- Bell WH, Levy BM. Revascularization and bone healing after posterior maxillary osteotomy. *J Oral Surg* 29:313-320, 1971.

- Choudhary S, Cadier MA, Shinn DL, et al. Effect of Veau-Wardill-Kilner type of cleft palate repair on long-term midfacial growth. *Plast Reconstr Surg* 111:576-582, 2003.
- Deluke DM, Marchand A, Robles EC, et al. Facial growth and the need for orthognathic surgery after cleft palate repair: literature review and report of 28 cases. *J Oral Maxillofac Surg* 55:694-697, 1997.
- Iannetti G, Casone P, Saltarel A, et al. Le Fort I in cleft patients: 20 years' experience. *J Craniofac Surg* 15:662-669, 2004.
- Polley JW, Figueroa AA. Rigid external distraction: its application in cleft maxillary deformities. *Plast Reconstr Surg* 102:1360-1372, 1998.
- Watzke I, Turvey TA, Warren DW, et al. Alterations in velopharyngeal function after maxillary advancement in cleft palate patients. *J Oral Maxillofac Surg* 48:685-689, 1990.
- Witzel MA, Munro IR. Velopharyngeal insufficiency after maxillary advancement. *Cleft Palate J* 14:176-180, 1977.

1
2
3
4
5
6
7
8
9
10
11
12
13
14
15
16
17
18
19
20
21
22
23
24
25
26
27
28
29
30
31
32
33
34
35
36
37
38
39
40
41
42
43
44
45
46
47
48
49
L